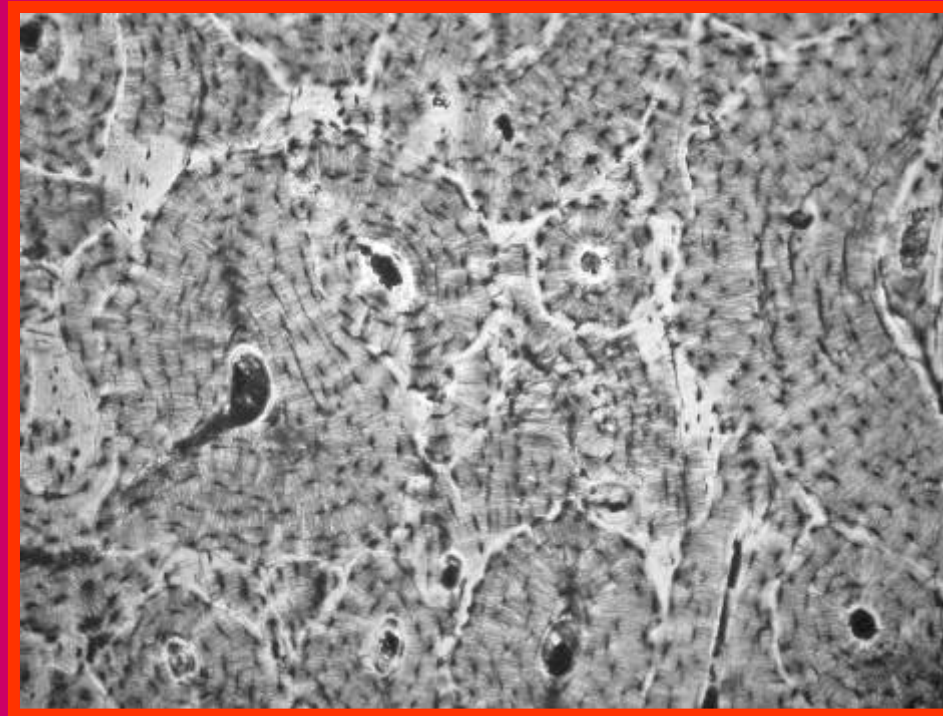
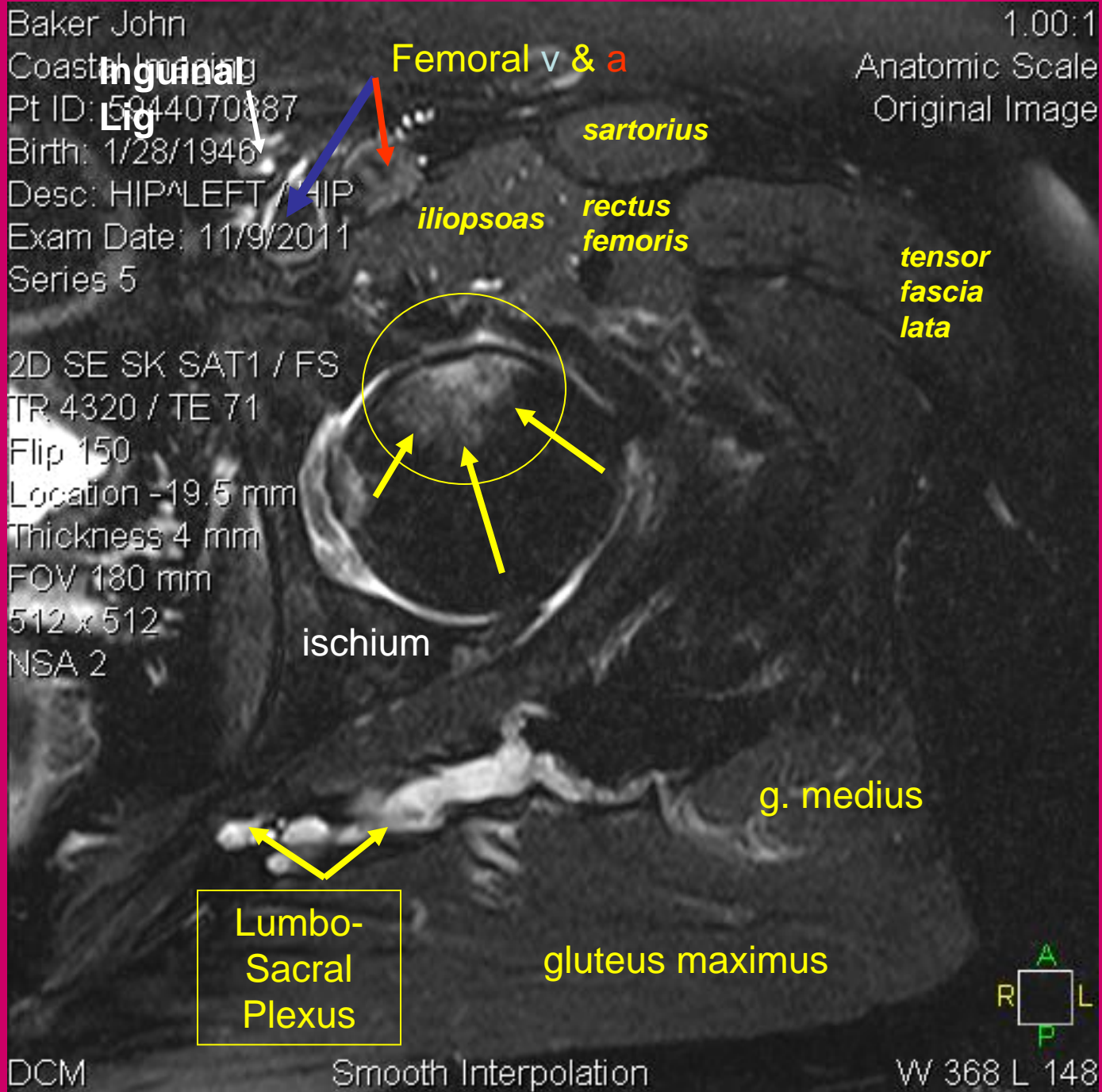


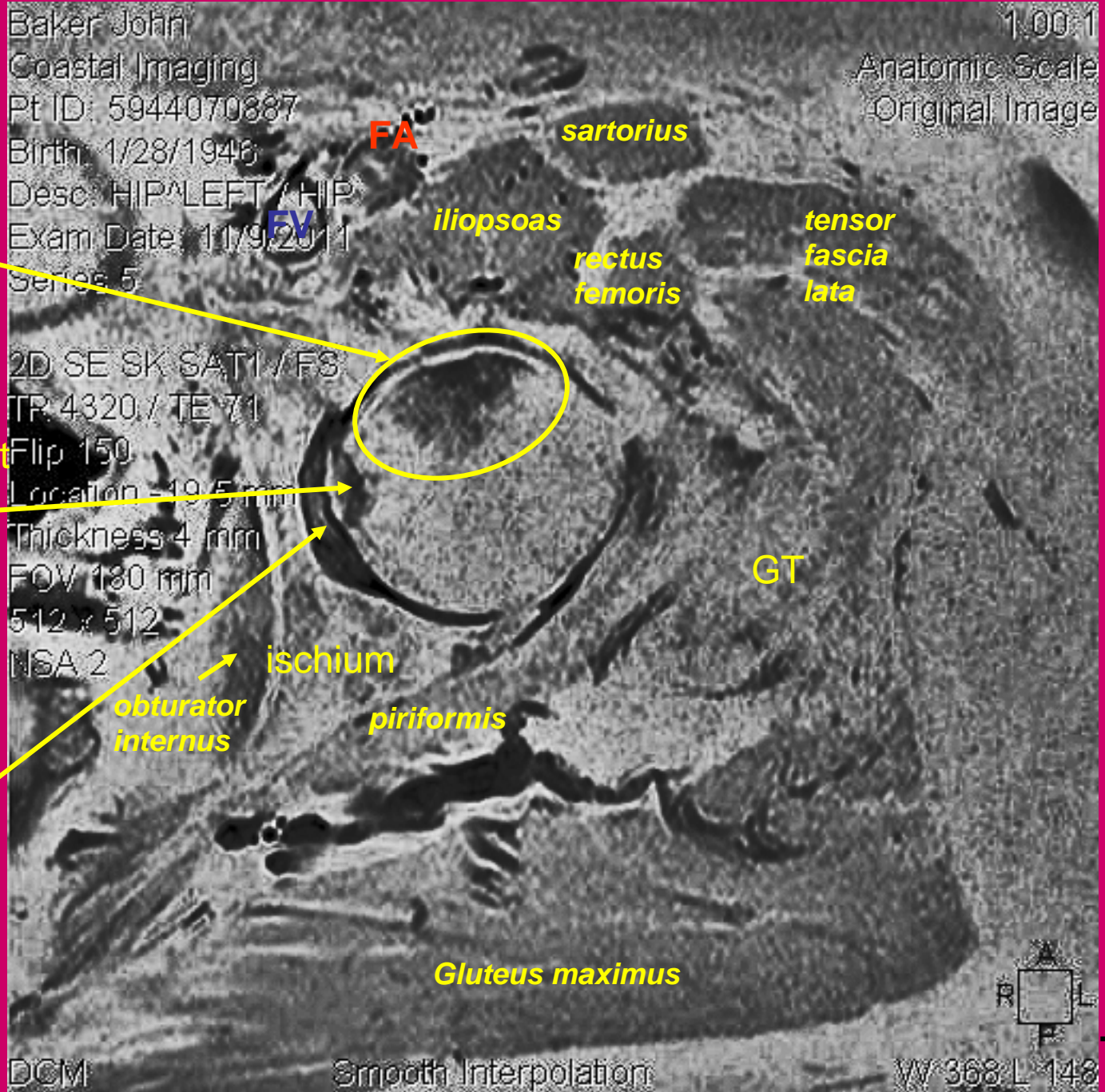
Radiologic, anatomic & surgical diagnosis & replacement of my left Hip Joint



Dried human bone thin
section: microscopic view

John EB Baker &
orthopedic surgeon
David Cashen MD





Circle:
necrotic
bone

'Fovea' or Pit
for
ligamentum
teres

Lig. Of
head of
femur

Transverse
view

Baker John E
COASTAL
Pt ID: 905344579887
Birth: 1/28/1945
Dept: PELVIS, GENERAL / PELVIS
Exam Date: 10/26/2011

1.001
Film Scale
Original Image

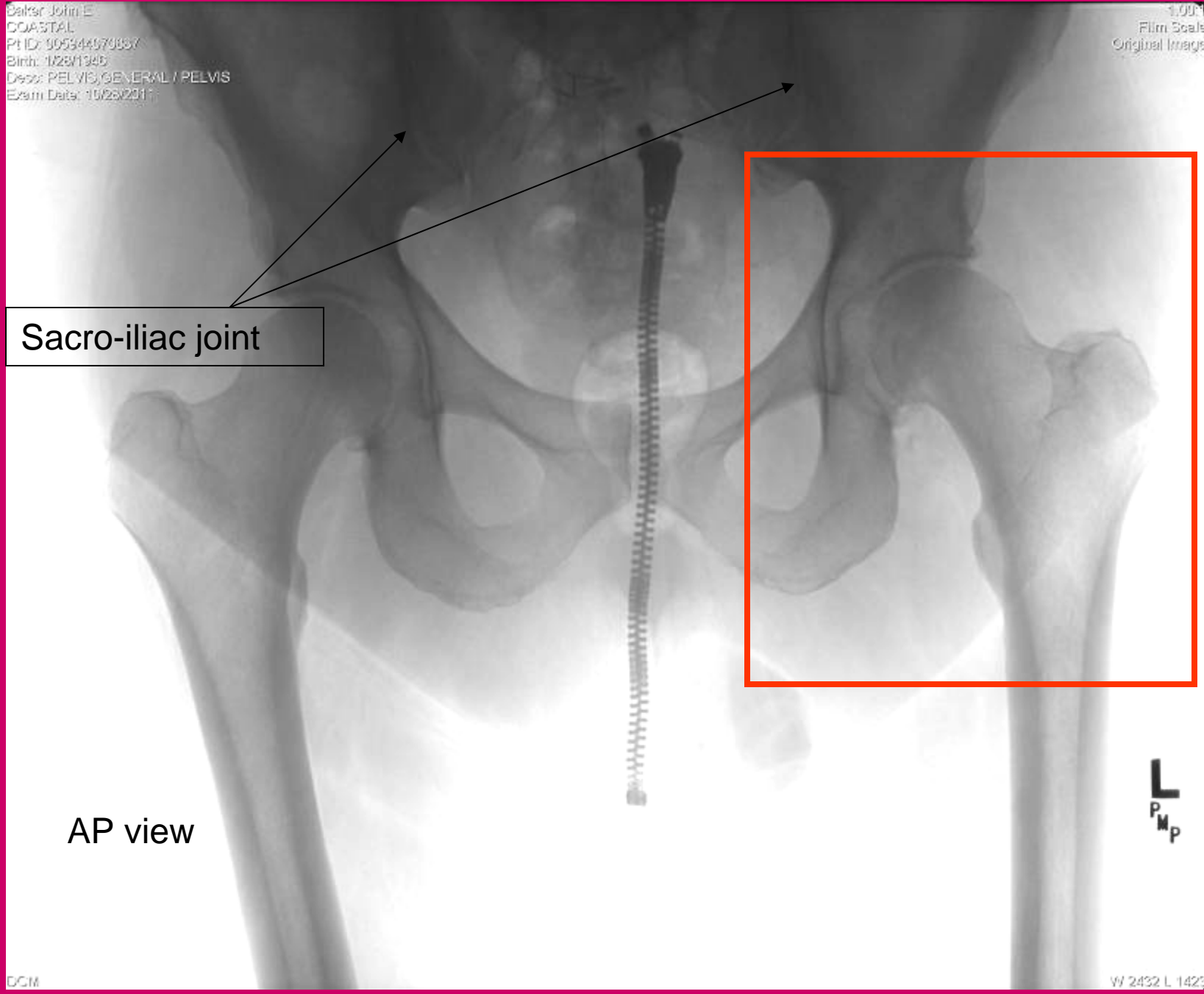
Sacro-iliac joint

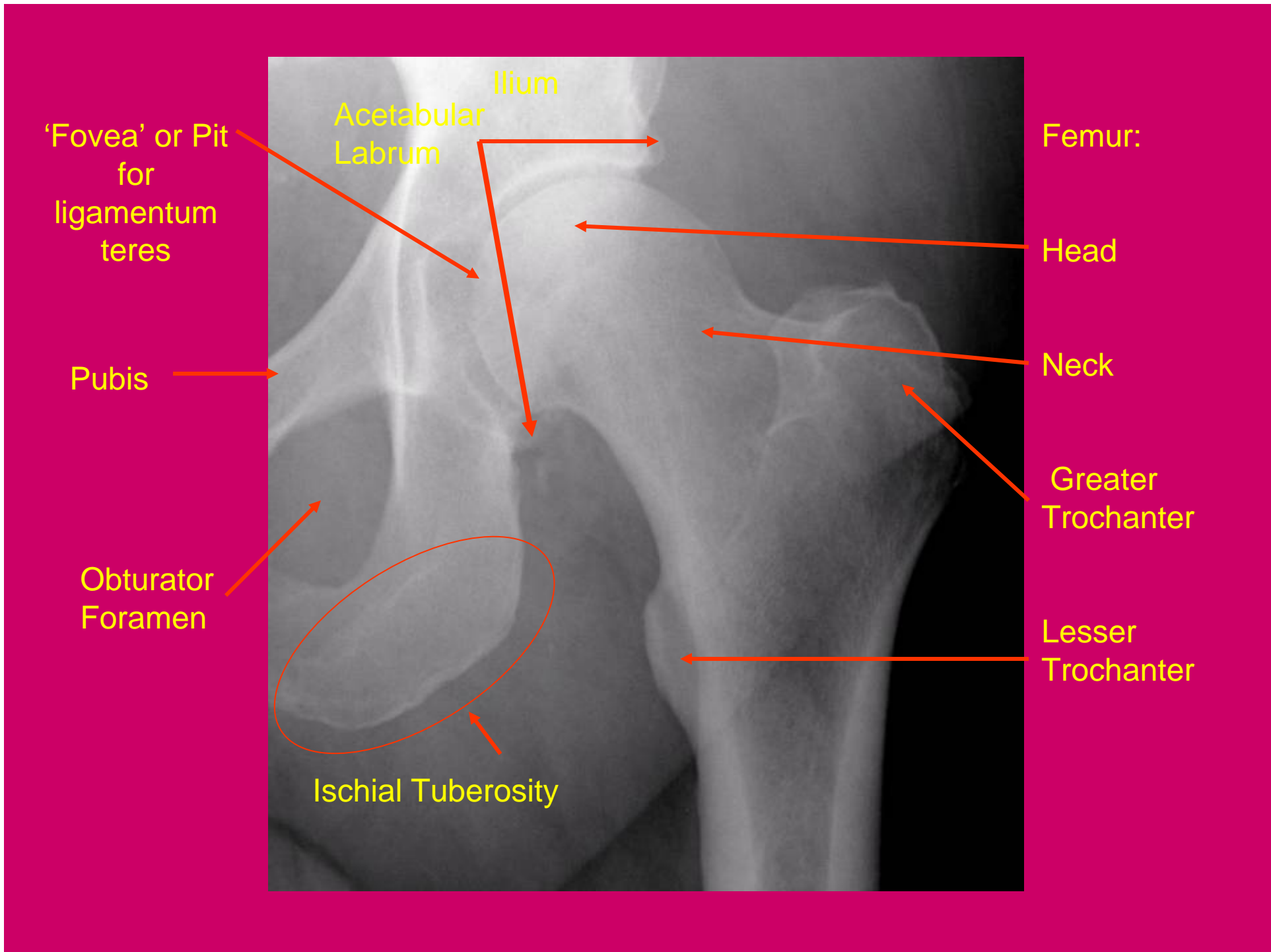
AP view

L
P
M
P

DCM

W 2432 L 1423





Baker John
Coastal Imaging
Pt ID: 5944070887
Birth: 1/28/1946
Desc: HIP^LEFT / HIP
Exam Date: 11/9/2011
Series 9

1.00:1
Anatomic Scale
Original Image

Ilium

Femur:

Acetabulum

Head

Neck

Greater
Trochanter

2D SE SK SAT2
TR 580 / TE 10
Flip 150
Location -36.5 mm
Thickness 3 mm
FOV 180 mm
512 x 512
NSA 2

piriformis

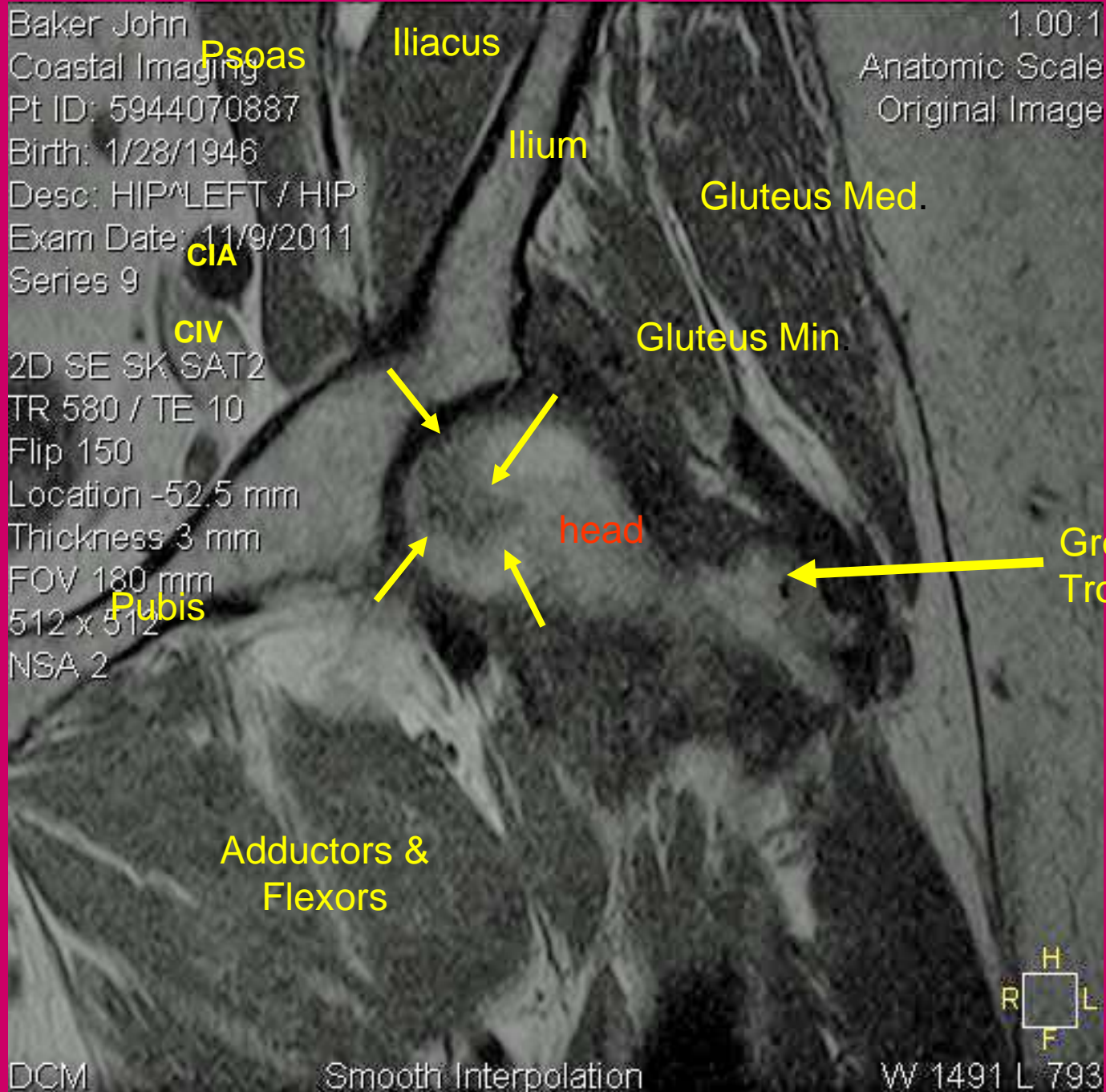
Coronal
view



DCM

Smooth Interpolation

W 1491 L 793



Arrows:
necrotic
bone

Coronal
view

fluoroscopy

J
BAKER

CASHEN

COASTAL ORTHO

12/16/11

11:09:59

Head

Neck

Dye in capsule
formed by 3
ligaments(IF, PF,
IsF)

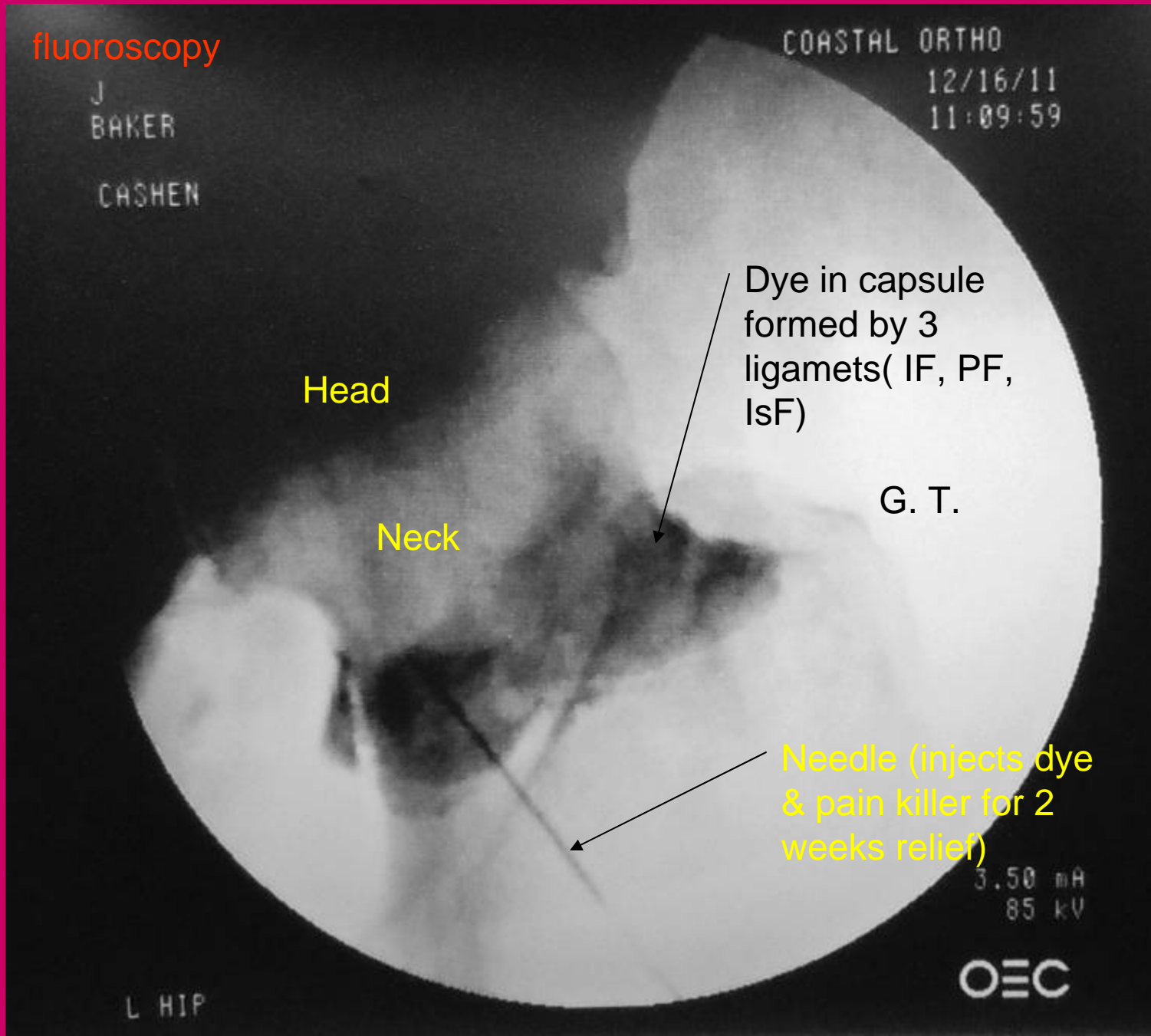
G. T.

Needle (injects dye
& pain killer for 2
weeks relief)

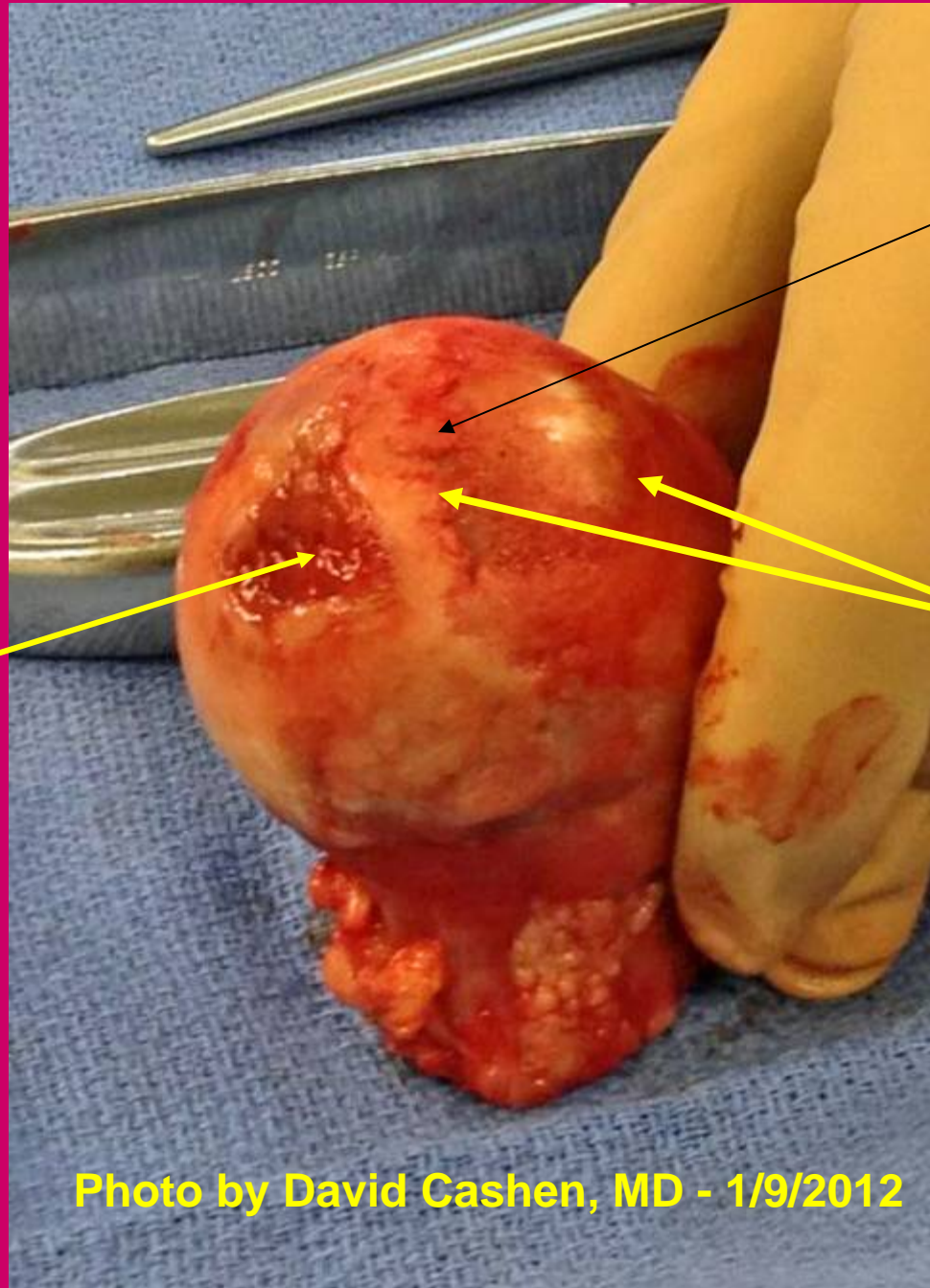
3.50 mA
85 kV

OEC

L HIP



My femur head after removal



Fovea (medial end)

Noted crenulate (zig-zag) edge of cartilage

Darker, eroded, superoanterior area where hyaline cartilage is missing = Osteoarthritis = pain; accelerated by underlying avascular necrosis ('AVN')

Photo by David Cashen, MD - 1/9/2012

Baker, John E
COASTAL
Pt ID: 005844070827
Birth: 1/28/1948
Desc: PELVIS, GENERAL / PELVIS
Exam Date: 1/27/2012

1.00:1
Film Scale
Original Image

Smith&nephew
'Anthology' Hip W/ R3°
Acetabular System

**My new, left
titanium hip 3
weeks after
surgery (A-P
radiograph)**

DCM

W 2426 L 1420

